

Torture by Introducing Foreign Object in Rectum: A Case Report

Mohd Kaleem Khan*, Manzoor Ahmad**, Shaukat A. Hanif***, Ansar UI Haq****

Abstract

Foreign body in the rectum has been reported frequently, attributed to whatever may be the cause. If the cause for it is assault or torture, then to quantify the trauma/pain either local or mental cannot be ascertained since it is a subjective matter although it is highly painful and embarrassing for the person who sustains the assault.

A unique case of assault for the purpose of torture given to a man about 30 years of age was encountered, that is a forceful insertion of a ceramic tea cup in the rectum by a group of people the reason being defecated in their field. Here we present the surgical and legal aspect of such case.

Keywords: Foreign object; Rectum; Assault; Medico-legal.

Introduction

Foreign bodies of different types have been reported earlier and most of the time the case is about sexual orientation or of sexual deviation.[1] Foreign bodies introduced in the rectum through the anal canal is mainly for sexual gratification and often it may slip from the grip of the person and get lodged in the rectum. This may be achieved by self introduction or by the help of a partner. [2,3,4,5] There are instances in which foreign bodies have been introduced in the rectum accidentally, still further as a means of assault or for the reason of torture. There are also researches of self introduction of drugs in rectum for the purpose of concealment has

often been reported in drug traffickers. In assault or torture [6]the legal aspect seems to be dependent on the outcome of the procedure applied for the removal of the body.

If removed through the anal route with no ill-effect the patient is discharged within 24 hours, then it is considered as simple hurt. If surgical intervention (laparotomy) is done then hospitalization may exceed 20 days (or the person is severe pain) then it is included in grievous hurt. If sufferer goes into a state of shock or peritonitis finally leading to death then it may be defined as murder.

Case report

A 30 year male resident of Kashiram Nagar of Uttar Pradesh (India) reported to the emergency department of JNMCH, AMU, Aligarh with severe pain in lower abdomen and bleeding from anus. He was brought at 2:00 PM on 28th of Oct. 2012 with an alleged history of forced insertion of ceramic tea cup in his rectum. As narrated by the patient he was defecating on a field which belonged to another person with whom they had old rivalry, the owner of the field along with some companions forcefully introduced the cup into his rectum warning him of dire consequences if he repeated the same mistake again. They

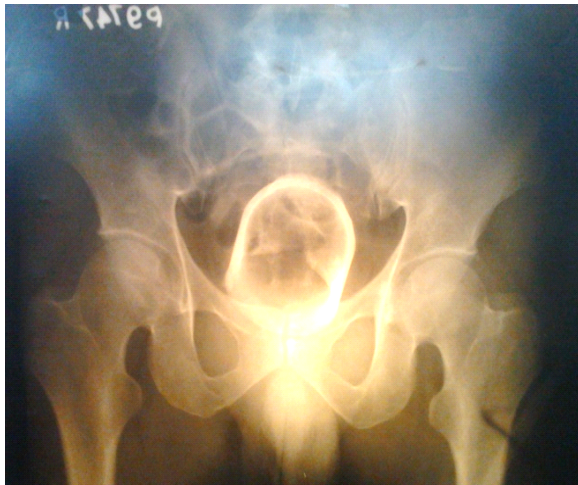Authors affiliation: *Senior Resident, Department of Forensic Medicine and Toxicology, ** Senior Resident, Department of Surgery, ***Associate Professor, Department of Forensic Medicine and Toxicology, ****Junior Resident, Department of Surgery, J.N. Medical College, Aligarh Muslim University, Aligarh, UP - 202002, India.

Reprints requests: Mohd Kaleem Khan, Senior Resident, Department of Forensic Medicine and Toxicology, J.N. Medical College, Aligarh Muslim University, Aligarh, UP - 202002, India.

E-mail: mkk435@yahoo.co.in

(Received on 18.02.2013, accepted on 18.03.2013)

X-ray of pelvis showing inverted cup in rectum with broken inlet



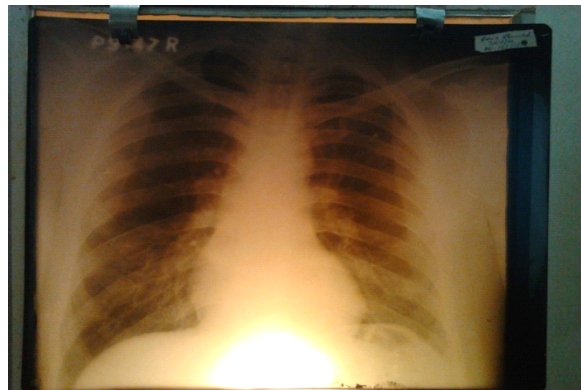
left him in the fields, when one of his relative him screaming for help. He was in great pain and could not walk. There was bleeding from the anal canal. On external examination bruises were present in the limbs both upper and lower and the back showed abrasion which were multiple. Abdomen was soft and non tender and locally little bleeding was found in anal region with bruising of the perianal tissue. Per rectal examination foreign body was found impacted above the dentate line in the anal canal. X-ray of abdomen showed an inverted cup in the region (about 100 ml capacity) of the pelvis. It could not be mobilized manually either externally or internally per rectum. The circular brim of cup inlet could be felt by the finger with one fourth of the circumference of the inlet brim broken.

Further investigation revealed that there was no gas under the diaphragm, therefore excluding perforation of the rectum and the adjoining area found. Foreign body was removed per rectum under spinal anesthesia due to which there was fresh bleeding. The cup could not be removed intact and had to be broken into several pieces for extraction. Further course was uneventful and the patient was discharged after two days.

Discussion

Foreign body in rectum introduced through

X-ray showing no gas under the diaphragm



anus may present under different scenario. It may be introduced by self or by partner in homosexuals or for the purpose of assault and torture. Self introduction of foreign body either for relief of craving (prostatic massage in absence of active partner in homosexuals) [1] or due to curiosity in young adults doing experimentation [7] is reported only after the foreign body slips beyond grip and self effort of extraction is not helpful to them and further assistance is required. foreign body introduced by partner [8] in homosexuals get sucked in rectum when it slips beyond grip or done deliberately to get rid off in hatred or partner is not faithful or partner is old. [1] Many a times may be introduced due to jealousy or in revenge. [1] There are cases reported for accidental insertion of foreign body in rectum [9], or seeking for medical attention, where cause could not be ascertained (Munchausen syndrome by proxy). [10]

The present case of an assault for the reason of torture presents with typical features. Along with pain and agony it had put the person in embarrassing situation (social stigma). In Social set up like that of Indian subcontinent such incidents derail the social and economic status of the person along with pain and suffering medically. The law doesn't deal with the mental trauma or social stigma attached to it and there is no provision made for rehabilitation of such a case. The present law deals with the outcome of the assault. In such an instance the assault may be covered under

Section 319, 321 and 323 IPC (Indian Penal

Code 1860)[11] if the treatment modality is simple extraction through anal route under spinal route then hospital stay is generally reduced to a day or two. Then the punishment is one year imprisonment, or with fine which may extend to one thousand rupees, or with both.

Section 320, 322 and 325 IPC (Indian Penal Code 1860)[12] Treatment warranting laparotomy for extraction of the body may extend the stay in hospital for more than 20 days or with severe bodily pain then punishment is imprisonment of either description for a term which may extend to seven years, and shall also be liable to fine.

If assault by dangerous weapon then punished under section 324 and 326 IPC (Indian Penal Code 1860)[13] and if assault leads to death then the assailant is tried for murder under Section 300 and 302 IPC (Indian Penal Code 1860).[14]

Ceramic cup is not covered under the definition of dangerous weapon thus over all act in this case falls under definition of simple injury. None of laws address the embarrassing stigma attached to it. Victims bearing such stigma had to face discrimination and social victimization for whole of their life similar to the victim of sexual assault. Time has reached to get stringent law to cover such an act specially, and further compoundability of sentences for such an embarrassing act provision for prohibition of revealing the identity of victim in media and also some rehabilitatory relief to victim.

Conclusion

- Any of the manipulation of the intimate parts for the reason of torture should be dealt seriously.
- Such acts are often done by group of people thus an act of furtherance of common intention therefore all of them should be punished equally.
- Monetary relief to the victim of such assault should be provided

- Further assistance in terms of medical, psychological and social should be provided to the victim.

References

1. James E Barone, Norman Sohn, T Thomas F Nealon Jr. Perforations and Foreign Bodies of the Rectum: Report of 28 Cases. *Ann. Surg.* 1976.
2. Jan Muhammad Memon *et al.* Rectal Foreign Body: Not a Rarity. *Gomal Journal of Medical Sciences.* 2007; 5(2).
3. Arkell M Vaughn, Michael S White. Foreign Body (Drinking Glass) in the Rectum. <http://jama.ama-assn.org/content/171/17/2307.extract>.
4. Y Narjis *et al.* Foreign body of the rectum: An unusual case. *J Emerg Trauma Shock.* 2010; 3(3): 306.
5. Akhtar MA, Arora PK. Case of unusual foreign body in the rectum. *Saudi J Gastroenterol.* 2009; 15: 131–2.
6. Shafi Muhammad Nizamani, Anshoo Agarwal, Hamid Ali, Siew S. Foreign Body Inserted In the Rectum as Torture and Related Medico Legal Issues. *Journal of Forensic Medicine & Toxicology.* 2010; 27(1).
7. Emil Mammadov, Altan Alim, Mehmet Elic, evik and Sinan Celayir. Self-induced penetrating rectal perforation by foreign body an unusual event in childhood. *Annals of Pediatric Surgery.* 2011; 7: 25–26.
8. Graves RW, Allison EJ Jr, Bass RR, *et al.* Analeroticism: two unusual rectal foreign bodies and their removal. *South Med J.* 1983; 76(5): 677-8.
9. Edward M Lowicki. Accidental Introduction of Giant Foreign Body into the Rectum: Case Report. *Annals of Surgery.* 1966.
10. Shakeeb A Khan *et al.* Munchausen's syndrome presenting as rectal foreign body insertion: a case report. *Cases Journal.* 2008; 1: 243. doi: 10.1186/1757-1626-1-243.
11. Section 319, 321 and 323 IPC (Indian Penal Code 1860) Accessed from: <http://www.Vakilno1.com/bare-acts/Indian-penal-code>. Accessed on 1st February 2012.
12. Section 320, 322 and 325 IPC (Indian Penal

- Code 1860) Accessed from: <http://www.Vakilno1.com/bare acts/Indian penal code>. Accessed on 1st February 2012.
13. Section 324 and 326 IPC (Indian Penal Code 1860) Accessed from: <http://www.Vakilno1.com/bare acts/Indian penal code>. Accessed on 1st February 2012.
14. Section 300 and 302 IPC (Indian Penal Code 1860) Accessed from: <http://www.Vakilno1.com/bare acts/Indian penal code>.
-

Instructions to Authors

Submission to the journal must comply with the Guidelines for Authors.
Non-compliant submission will be returned to the author for correction.

To access the online submission system and for the most up-to-date version of the Guide for Authors please visit:

<http://www.rfppl.com>

Technical problems or general questions on publishing with **IJFMP** are supported by Red Flower Publication Pvt. Ltd's Author Support team (<http://www.rfppl.com>)

Alternatively, please contact the Journal's Editorial Office for further assistance.

A Lal

Publication -in-Charge

Indian Journal of Forensic Medicine and Pathology

Red Flower Publication Pvt. Ltd.

48/41-42, DSIDC, Pocket-II

Mayur Vihar Phase-I

Delhi – 110 091

India

Phone: 91-11-22754205, Fax: 91-11-22754205

E-mail: redflowerppl@gmail.com

Website: www.rfppl.com